

Successful endovascular treatment of carotid artery injury following hemodialysis catheter insertion

Zaur Guseinov , Merve Topcu , Kocaaslan Cemal , Ebuzer Aydın 

Department of Cardiovascular Surgery, Medeniyet University Faculty of Medicine, İstanbul, Türkiye

Received: March 27, 2025 Accepted: May 18, 2025 Published online: June 13, 2025

ABSTRACT

Although arteriovenous fistulas are the first choice for hemodialysis, failure of an existing vascular access site may necessitate urgent central venous catheter placement. Herein, we presented a 65-year-old male patient with chronic kidney disease who presented to the emergency department for dialysis. Following evaluation, the patient was admitted to the emergency angiography unit after a carotid artery injury was detected. Extravasation was detected in the carotid artery during the procedure. The carotid artery injury was successfully managed through endovascular stent placement. No extravasation was observed on the control radiograph. Although arteriovenous fistulas have many advantages, some patients may require dialysis catheters.

Keywords: Carotid artery, computed tomography angiography, extravasation, hemodialysis catheter.

Central venous catheterization is a frequently required procedure in patients undergoing chronic hemodialysis. Although arteriovenous fistulas are the preferred method for vascular access, complications or failure of the existing access route may necessitate the use of central venous catheters. The right internal jugular vein is the most commonly used site for catheterization. However, the femoral veins may be used in emergency situations, or in cases where the internal jugular vein is occluded or there is an intracardiac thrombus.^[1] In emergency settings, femoral vein catheterization is often preferred due to the absence of risks such as hemothorax and pneumothorax. Nevertheless, because the internal jugular vein is considered a cleaner site compared to the femoral vein, it carries a lower risk of catheter-related infections. Regardless of the access site, close monitoring is recommended for all patients, as the procedure is invasive.^[2] In this study, we presented the complications that occurred during catheter insertion in a patient with chronic kidney disease, along with the interventions we performed.

and a previous colectomy for a colorectal tumor was admitted to the emergency department with complaints of diarrhea. The patient was under the ongoing care of both a cardiologist and a nephrologist and was receiving regular hemodialysis sessions for chronic renal failure. The patient was hypotensive upon arrival at the emergency department. The cardiology department was consulted to rule out acute coronary syndrome, and troponin levels were monitored, which ultimately excluded the diagnosis of acute coronary syndrome. Following the results of the tests, the patient was admitted to the internal medicine service with a preliminary diagnosis of prerenal acute renal failure. A consultation with the nephrology clinic was requested; however, emergency hemodialysis could not be initiated due to the patient's hypotensive condition (98/67 mmHg).

Corresponding author: Zaur Guseinov, MD. Department of Cardiovascular Surgery, Medeniyet University Faculty of Medicine, 34700 Üsküdar, İstanbul, Türkiye.
E-mail: guseynovzaur4@gmail.com

Citation:

Guseinov Z, Topcu M, Cemal K, Aydın E. Successful endovascular treatment of carotid artery injury following hemodialysis catheter insertion. *Cardiovasc Surg Int* 2025;12(2):164-167. doi: 10.5606/e-cvsi.2025.1878.

CASE REPORT

A 65-year-old male patient with a history of chronic hypertension, chronic kidney disease,

On physical examination, the Glasgow Coma Scale score was 15, with the patient being conscious, clear, coherent, and oriented. Respiratory sounds were diminished on the left side and were normal on the right. Written informed consent was obtained from the patient.

The abdomen was soft, with no signs of defense or rebound tenderness. Bowel sounds were hyperactive. The patient appeared cachectic and dehydrated. The patient's colostomy was functioning, and diarrhea was present with accompanying gas discharge. Neurological examination was normal, and muscle strength was 5/5 bilaterally in both the upper and lower extremities. The patient was monitored in the internal medicine ward and subsequently discharged. However, due to the need for hemodialysis, the patient was readmitted to the emergency department for central venous catheter insertion.

Following insertion of a dialysis catheter through the right internal jugular vein, the patient's general condition deteriorated. Thoracic computed tomography angiography was performed, and our team was subsequently consulted (Figures 1, 2). The patient and investigations were evaluated urgently by our team and the thoracic surgery team. The patient was taken to the emergency angiography unit. After sterile preparation and local anesthesia, a 6F sheath was inserted into the right femoral artery under ultrasound guidance. A 0.035-inch hydrophilic wire was then advanced with vertebral catheter support.

Imaging was performed, and a wire was inserted into a temporary catheter in the right internal jugular vein. Additional imaging was conducted as the catheter was withdrawn. It was observed that the catheter had exited the jugular vein and inadvertently punctured the right carotid artery. Extravasation from the right carotid artery was noted (Figure 3). The catheter, which had been mistakenly inserted into the carotid artery, was repositioned back to its original location and secured. Subsequently, a temporary dialysis catheter was successfully placed through the right femoral vein. The patient was monitored with further investigations, and the procedure was completed without complications. For additional procedures, the patient was re-evaluated. Initially, a sternotomy extending to the right carotid region was considered

to ensure thorough exploration. However, due to the patient's poor general condition and the high surgical risk, the decision was made to proceed with angiography and endovascular intervention instead. The patient was transferred to the angiography laboratory, where, following sterile draping and administration of local anesthesia, a sheath was inserted into the left femoral artery through a puncture guided by ultrasonography. A 0.035-inch hydrophilic wire was introduced through the vertebral catheter, followed by control imaging. Finally, a pigtail catheter was placed to complete the procedure. The catheter in the right jugular vein was withdrawn and an 8×60 mm Cover Wall

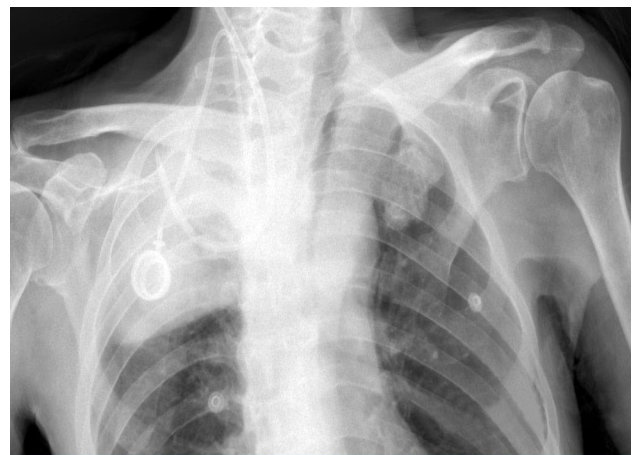

Figure 1. Chest radiograph demonstrating interposition of the right dialysis catheter.

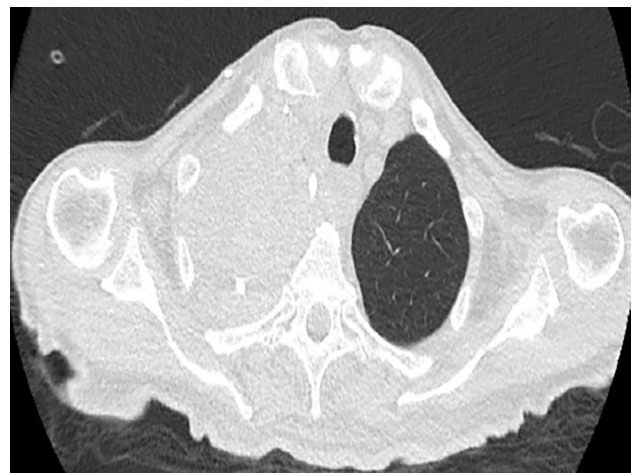


Figure 2. Computed tomography angiography demonstrating right hemothorax and contrast accumulation in the right pleural cavity.

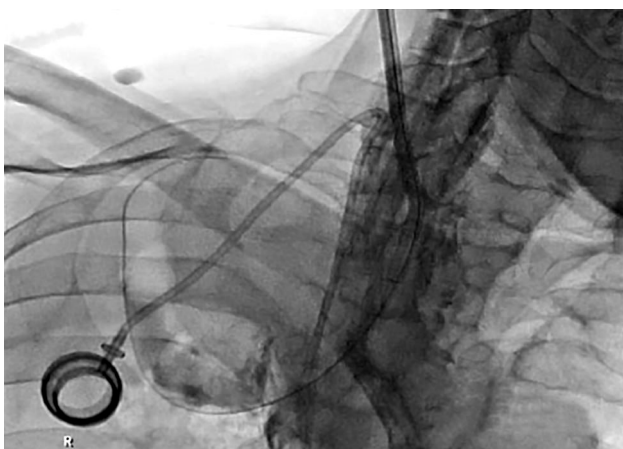


Figure 3. Extravasation detected during angiography imaging. The catheter exits beyond the carotid artery.

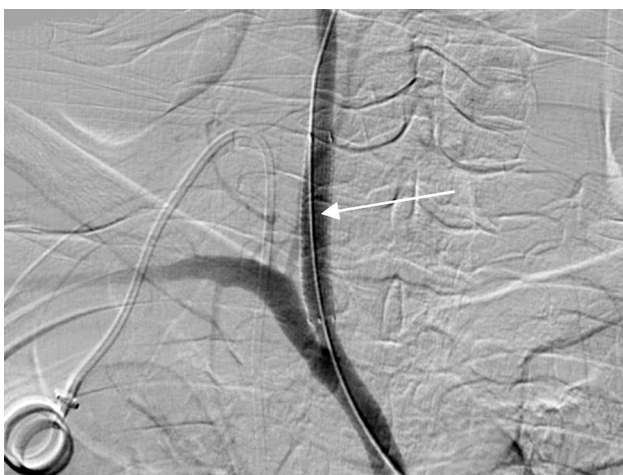

Figure 4. Cover Wall stent placement in the proximal part of the right carotid artery.

stent (Carotid Wallstent Monorail Endoprosthesis, 8×38 mm; Boston Scientific, Marlborough, MA, USA) was placed in the proximal segment of the right common carotid artery. Control imaging was performed and no extravasation was observed. The procedure was terminated without complications (Figure 4). The patient had an uneventful postoperative course and was discharged in good general condition after a week of follow-up.

DISCUSSION

Vascular access for dialysis catheters in chronic hemodialysis patients remains a challenging issue,

often leading to significant complications. While arteriovenous fistulas offer numerous benefits, dialysis catheters may still be necessary for some patients. The right internal jugular vein should be the first choice for venous catheter placement.^[3] However, complications such as venous thrombosis, arterial puncture, hemothorax, and pneumothorax can arise when catheters are placed via the subclavian vein.^[4] In cases of jugular vein thrombosis, infection at the catheter insertion site, lesions that may obstruct catheter placement, or the presence of intracardiac thrombus, the femoral vein can be considered an alternative access point. Although the femoral site is generally cleaner, the jugular region remains technically challenging for puncture. Hemothorax, a condition that leads to hemodynamic disturbances, is typically caused by catheter extravasation. This is more common with temporary catheters than with permanent ones due to the rigid structure of temporary catheters. It is detected by the absence of blood from the catheter or extravasation of contrast material given by imaging methods. In our case, extravasation was observed on computed tomography. According to the literature, in case of damage to the carotid arteries, a classic approach is used for better visualization of the vessels. This approach is performed by an incision parallel to the anterior edge of the midclavicular mastoid muscle. This allows timely access to the carotid arteries and the necessary interventions to eliminate bleeding. In such emergency situations, specifically in our case, this approach could be used to ensure better and timely visualization of the arteries. However, when choosing the treatment tactics, the severe general condition of the patient expressed by unstable hemodynamics was taken into account. Since the patient had a significant concomitant disease and unstable hemodynamics, we considered endovascular intervention with angiography more appropriate. In the educational literature and in scientific articles, the approach to the treatment of such complications is rarely described. The reason for this may be the untimely provision of bleeding control. However, the clinical approach and tactics of treating these complications should be based on the general condition of the patient.

In conclusion, vascular access for chronic hemodialysis remains a significant clinical challenge due to the risk of serious complications. Although

the internal jugular vein is generally the preferred site, alternative access via the femoral vein may be necessary in certain cases. Potential complications include thrombosis, hemothorax, and catheter extravasation. In the presented case, due to the patient's hemodynamic instability, an endovascular approach with angiographic guidance was selected. Ultimately, the choice of treatment strategy should be based on the patient's overall clinical condition.

Data Sharing Statement: The data that support the findings of this study are available from the corresponding author upon reasonable request.

Author Contributions: All authors contributed equally to this article.

Conflict of Interest: The authors declared no conflicts of interest with respect to the authorship and/or publication of this article.

Funding: The authors received no financial support for the research and/or authorship of this article.

REFERENCES

1. Frykholm P, Pikwer A, Hammarskjöld F, Larsson AT, Lindgren S, Lindwall R, et al. Clinical guidelines on central venous catheterisation. Swedish Society of Anaesthesiology and Intensive Care Medicine. *Acta Anaesthesiol Scand* 2014;58:508-24. doi: 10.1111/aas.12295.
2. Eisen LA, Narasimhan M, Berger JS, Mayo PH, Rosen MJ, Schneider RF. Mechanical complications of central venous catheters. *J Intensive Care Med* 2006;21:40-6. doi: 10.1177/0885066605280884.
3. Ishizuka M, Nagata H, Takagi K, Kubota K. Right internal jugular vein is recommended for central venous catheterization. *J Invest Surg* 2010;23:110-4. doi: 10.3109/08941930903469342.
4. Sanrı US, Katrancıoğlu N. Venous port catheter dislocation as an unusual cause of pneumonia *Dicle Med J* 2014;40:418-420.